
RESEARCH ARTICLE

A Therapeutic Challenge: Management of Atrial Thrombus

Serkan Burç Deşer, Mustafa Kemal Demirağ

Department of Cardiovascular Surgery, Faculty of Medicine, 19 Mayıs University, Samsun, Turkey

ABSTRACT

Introduction: Primary cause of atrial thrombi include atrial fibrillation, foreign bodies inside the atrium such as catheters and pacemaker leads, emboli of deep venous thrombus and primary or metastatic tumors of the heart. We review the clinical features, epidemiology, diagnosis and treatment of nine intriguing cases with atrial thrombus.

Methods: This is a retrospective study of nine patients (seven female (78%), two male (33%)) who were diagnosed with atrial thrombi (average age of 50 ± 12 years) and were treated at the Ondokuz Mayıs University, Department of Cardiovascular Surgery from February 2014 to January 2015. Among them, six patients had atrial fibrillation (one male, five female), seven patients were suffering from dispne and orthopnoea, five patients were suffering from leg swelling, seven patients had a history of hypertension and three patients had a history of mitral valve replacement surgery.

Results: All patients underwent surgery except one. Four patients recovered uneventfully and discharged with oral anticoagulation (warfarin) therapy (adjusted to maintain an international normalized ratio of INR between two and three times). Five of nine patients (55%) died after surgery.

Conclusion: The response to the thrombolytic therapy is poor, mostly ineffective and unsafe so it is often recommended as a bridge to surgery. In patients diagnosed with mechanical mitral valve thrombosis, medical therapy has the possibility of end organ emboli and also fail to resolve the organised thrombus on the stuck valve. On the other hand surgery does not always give satisfactory results. *J Clin Exp Invest 2016; 7(4): 278-282*

Keywords: Thrombus, atrium, treatment

INTRODUCTION

Atrial thrombus was first described via an autopsy in 1814. Primary causes of atrial thrombi include atrial fibrillation, foreign bodies inside the atrium such as catheters and pacemaker leads, emboli of deep venous thrombus and primary or metastatic tumors of the heart. Also breast cancer, lung cancer, lymphoma, melanoma and sarcoma which can metastasize to the heart, are seen 20 times more than the primary tumors of the heart and are often regarded as atrial tumor thrombi. Patients, who are diagnosed with atrial fibrillation, are usually presented with progressive dyspnea and orthopnea. Transthoracic transesophageal echocardiography, contrast enhanced computed

tomography and magnetic resonance are used for diagnosing. If left untreated, masses that totally fill the atrium can cause life-threatening conditions [1]. Urgent surgery is usually indicated in patients with massive pulmonary embolism, progressive valve obstruction or heart failure. Systemic thrombolytic therapy can be used for pulmonary thromboembolism or can be used as a bridge therapy to primary surgical treatment for free-floating emboli in the right atrium. Thrombolytic therapy for left atrial thrombus is ineffective and unsafe due to possible risks for embolus [2]. Atrial thrombus treatment strategy still remains controversial. It may embolize at any time with high mortality rate (40%). In case of emboli, urgent intervention may be required. We review the clinical features,

Correspondence: Dr. Serkan Burç Deşer, Ondokuz Mayıs University, Medical Faculty, Department of Cardiovascular Surgery, Samsun, Turkey

E-mail: sbd983@yahoo.com

Received: 28 October 2016, Accepted: 24 December 2016

Copyright © JCEI / Journal of Clinical and Experimental Investigations 2016, All rights reserved

epidemiology, diagnosis and treatment of 9 intriguing cases with atrial thrombus.

METHODS

This is a retrospective study, for this reason ethics committee approval was not taken. This study consist of 9 patients (7 (78%) female, 2 (33%) male) who were diagnosed with atrial thrombi (average age of 50 ± 12 years) and were treated at the Ondokuz Mayıs University, Department of Cardiovascular Surgery from February 2014 to January 2015. Data collection included the indication for interventions, treatment details and perioperative outcomes. 6 patients had atrial fibrillation (1 male, 5 female), 7 patients were suffering from dyspnea and orthopnea, 5 patients were suffering from leg swelling, 7 patients had a history of HT, 3 patients had a history of mitral valve replacement surgery and 1 patient had a history of both aortic and mitral valve replacement surgery.

Informed consent was taken from all patients.

Statistical analysis

Due to low volume of patients, there was no need for statistical analysis in this retrospective study.

RESULTS

Two (22%) patients were male and seven (78%) patients were female. One (11%) patient had an AV complete block, two (22%) patients were in sinus rhythm and six (66%) patients were in atrial fibrillation. Four (44%) patients had a history of inappropriate administration of Coumadin therapy. Low molecular weight heparin (LMWH) therapy was administered after surgery; four (44%) patients were discharged with oral anticoagulation (warfarin) therapy (adjusted to maintain an international normalized ratio of INR two or three times). Unfortunately five (55%) of nine patients was lost after surgery (Table 1).

Case 1

A 47-year-old female presented with progressive orthopnea, dyspnea and atrial fibrillation, was admitted to our clinic. Transthoracic echocardiogram revealed a large right atrial

mass (thrombus/myxoma) which was adhered to lateral wall of the right atrium and severe tricuspid valve insufficiency (Figure 1a). The 5 cm×6 cm×7 cm in size mass was mimicking atrial myxoma with thrombus. Atrial thrombus and tricuspid valve were completely excised and 33 no bovine bioprostheses valve (Bioprostheses: St Jude, Minn. USA) was replaced. The postoperative course was uneventful and she was discharged with oral warfarin therapy one week after the surgery.

Case 2

A 65-year-old female presented with progressive shortness of breath and swelling on her both legs was admitted to the emergency department. The patient had a history of pacemaker implantation due to atrio-ventricular complete block, which had been placed 12 years ago. Echocardiography revealed thrombus attached to the pacing lead in the right atrium and grade-3 tricuspid regurgitation. A computerized tomography (CT) scan confirmed the presence of a 3x5 cm in size thrombus around the catheter lead, in the superior vena cava and in the right atrium. The tricuspid valve was replaced with 33 no bovine bioprostheses valve (Bioprostheses: St Jude, Minn. USA). The internal leads with thrombus was excised and replaced with permanent external pacemaker leads. Over the following days, the patient developed a respiratory infection with progressive clinical deterioration that led to sepsis and despite intensive antibiotic therapy, she progressively deteriorated and died.

Case 3

A 63 year old female with long standing history of Alzheimer's disease, diabetes mellitus, hypertension, cerebrovascular disease and atrial fibrillation was referred to our department on account of worsening acute ischemia (pulseless, pain, cold, pale and cyanotic) of her right limb. Echocardiography revealed a 2.5x1.1 cm in size mass within the left atrium and Doppler ultrasound revealed thrombus in the right common femoral artery. Thrombi on the left atrium and right femoral artery were excised (Figure 1b). Over the following days, her right limb worsened and was amputated above the knee. On the post-operative 15th day, a respiratory infection developed with progressive clinical deterioration and the patient died.

Case 4

A 52-year-old female patient presented with progressive shortness of breath was admitted to the emergency department. She had a history of mitral valve replacement in 2003. Patient did not take her medications regularly and the initial laboratory clotting analysis revealed an international normalized ratio (INR) of 1.3. Transthoracic echocardiogram revealed dilated left atrium containing a 1.5x2.4 cm in size highly mobile mass relevant with the mechanical valve. Mitral valve and thrombus were excised and was replaced with 31 no mechanical valve (Mechanical; St Jude, Minn. USA). The postoperative course was uneventful and she was discharged on post-operative 5th day with oral warfarin therapy.

Case 5

A 67-year-old female presented with progressive shortness of breath and swelling in her legs was admitted to the emergency department. She had a history of mitral valve replacement with mechanical valve in 2007. She terminated anticoagulant therapy by herself due to nausea. Echocardiogram revealed a 2.3x2 cm in size highly mobile mass relevant with the mechanical valve. Mitral valve and thrombus were excised and was replaced with 29 no bovine bioprostheses valve (Bioprostheses; St Jude, Minn. USA). She recovered uneventfully and discharged 7 days later with oral warfarin therapy.

Case 6

An 18-year-old female presented with progressive shortness of breath was admitted to the emergency department. She had a history of chronic renal insufficiency. Transthoracic echocardiogram revealed a 5x5 cm in size highly mobile mass attached to the top of the catheter. After 1 week of intravenous heparin administration, echocardiography was repeated and showed that the thrombus was dissolved. Patient was discharged uneventfully with oral warfarin therapy.

Case 7

A 54-year-old male presented with progressive shortness of breath and swelling in the legs was admitted to the emergency department. He had a history of aortic and mitral valve replacement. Echocardiography revealed severe aortic insufficiency and pannus on the ventricular site. 21 no mechanical aortic valve (St Jude, Mechanical, Minn. USA) and 29 no mechanical mitral valve (Mechanical, St Jude, Minn. USA) were replaced. On the post-operative first day, the patient progressively deteriorated and died.

Case 8

A 30-year-old female presented with severe shortness of breath and swelling in her legs was admitted to the cardiology clinic. She had a history of mitral valve replacement surgery, which was repeated three times.

Table 1. Baseline characteristics of the study population.

Age	Sex	Comorbidity	Atrial fibrillation	Orthopnea	Dispnea	Leg Swelling	Mass size (cm)	Previous surgery	Treatment modality	Age
47	F	HT	+	+	+	-	5x6x7	-	surgery	47
65	F	HT, hypothyroiditis, atrioventricular complete block	-	+	+	-	3x5	-	surgery	65
63	F	Alzheimer's dementia, DM, HT, cerebrovascular disease	+	-	-	-	2.1x1x1	-	surgery	63
52	F	HT, hypercholesterolemia	+	+	+	-	1,5x2x4	MVR	surgery	52
67	F	HT	+	+	+	+	2,3x2	MVR	surgery	67
18	F	Chronic renal insufficiency, HT	-	-	-	+	5x5	-	conservative	18
54	M	HT	+	+	+	+	2.1x1.8	AVR + MVR	surgery	54
30	F	Rheumatic heart disease	+	+	+	+	1.5x2	3 times MVR	surgery	30
41	M	Patent foramen ovale	-	+	+	-	4x3	-	surgery	41

DM=Diabetes Mellitus, HT=Hypertension

Echocardiography revealed massive thrombus on the atrial site of the previous mechanical valve (Figure 1c). On pump beating heart, mitral valve surgery via a right thoracotomy was performed and 27 mm mechanical valve (Mechanical, St Jude, Minn. USA) was replaced. On post-operative 10th day, the patient developed a respiratory infection with progressive clinical deterioration and died.

Case 9

A 41-year-old male presented with severe shortness of breath was admitted to the emergency department. Echocardiography revealed thrombus on the left atrium, right atrium, inferior vena cava, and patent foramen ovale, pulmonary artery pressure was 90 mm Hg and right ventricle was globally hypokinetic. Computed tomography showed total occlusion of the right main pulmonary artery and huge thrombus on the left main pulmonary artery and branches. Emergency surgery was performed via right atriotomy, left atriotomy and pulmonary arteriotomy. Thrombus debris was excised from right atrium, left atrium, inferior vena cava, right main pulmonary artery and left main pulmonary artery (Figure 2a, 2b). Patient's foramen ovale was repaired with pericardium. Nevertheless, urgent diagnosis was made and surgery was performed, patient did not weaned from heart-lung machine due to globally hypokinetic right ventricle and died.

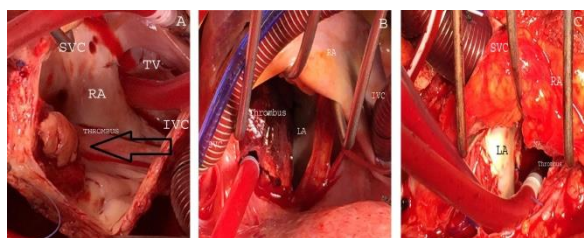

Figure 1: (a) Intraoperative image of right atrial (RA) thrombus. Superior vena cava (SVC), Inferior vena cava (IVC), Tricuspid valve (TV). (b) Intraoperative image of left atrial (LA) thrombus. Superior vena cava (SVC), Inferior vena cava (IVC), Right atrium (RA), (c) Intraoperative image of left atrial (LA) thrombus. Superior vena cava (SVC), Right atrium (RA), Mitral valve (MV).

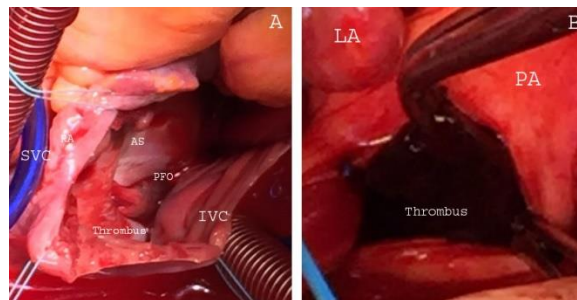


Figure 2. Intraoperative image of biatrial (LA) thrombus (A) and pulmonary embolus (B). Superior vena cava (SVC), Inferior vena cava (IVC), Right atrium (RA), Pulmonary Artery (PA), Patent foramen ovale (PFO), Atrial septum (AS).

DISCUSSION

The etiology of thrombus comprises structural cardiac disease, atrial fibrillation and metastatic carcinoma. Atrial fibrillation is associated with thromboembolism including stroke and pulmonary embolism. Left atrial thrombus is often associated with mitral valve stenosis, atrial fibrillation, hypertrophic cardiomyopathy and patent foramen ovale. Association of atrial fibrillation with stroke is 5% to 12% per year. Anticoagulation therapy with oral warfarin reduces stroke incidence to 37% to 86%. Risk of bleeding with warfarin is 0.5% to 2.8% per year [3]. Advanced ages, diabetes mellitus, heart failure, history of previous myocardial infarction and embolism increase the risk of stroke in patients with atrial fibrillation [4]. Chronic atrial fibrillation leads to fibrotic changes in the myocardium which leads to enlargement of the atrium and loss of function. Tachycardia leads to cardiomyopathy on account of atrial fibrillation [5]. Thrombus can be seen in %20-40 of patients after implantation of internal pacemaker leads however, symptomatic thrombus may occurs in 1-3% of the patients and have a high risk of pulmonary embolism. The presence of atrial thrombus can cause inflow and outflow obstruction. Right atrium masses lead to hemodynamic changes and mimic tricuspid stenosis and pulmonary embolism, which may present with tiredness, hepatomegaly, ascites, leg-facial-arm swelling or pain, discoloration, visible collateral circulation and superior vena cava syndrome [6]. On physical examination, regurgitation and apical systolic murmur can rarely be heard. The diagnosis of atrial thrombus

is usually made by transthoracic or transesophageal echocardiography however, it provides poor sensitivity for small thrombus that can be overlooked [7]. A fluoroscopic imaging of restricted disc movement helps diagnose valve stagnation and thrombus. Cardiac catheterization usually helps the diagnosis of mitral or tricuspid obstruction. Complications of anticoagulation therapy with warfarin or warfarin like drugs are independent from the type of prosthesis and suboptimal anticoagulant therapy also leads to thrombus [8,9]. Thrombosis of mechanical valves is seen more often than the bioprosthetic valves [10].

Conclusion

Warfarin is the first treatment option for valvular/non-valvular atrial fibrillation or after valve replacement to prevent peripheral embolism or thrombus formation in the atriums/valves. To avoid thrombus formation in the atrium and fatal complications, patients should be aware of the importance of Coumadin administration. In case of life threatening conditions such as atrial thrombus associated with massive pulmonary embolism, acute valve obstruction and heart failure, emergency surgery can be a treatment of choice. However, removal of the thrombus concomitant with mitral valve repair or replacement is recommended during surgery. The response to the thrombolytic therapy is poor, mostly ineffective and unsafe so it is often recommended as a bridge therapy to surgery for left atrial thrombus. Diagnosis and treatment of atrial thrombus is essential and is a therapeutic challenge and attention must be paid to choose the appropriate treatment strategy. Nevertheless, medical therapy should be kept in mind for primary treatment or as a bridge to surgery for all patients. In patients with isolated right atrial thrombus, surgical treatment gives good results if medical therapy is insufficient. In patients diagnosed with mechanical mitral valve thrombus, medical therapy has possibility of end organ thrombus and also fails to resolve the organized thrombus on the stuck valve. On the other hand surgery does not always give satisfactory results.

Declaration of conflicting interests: The authors declared no conflicts of interest with respect to the authorship and/or authorship of this article.

Funding: The authors received no financial support for the research and/or authorship of this article.

REFERENCES

1. Sheikh A, Schrepfer S, Stein W, et al. Right atrial mass after primary repair of an atrial septal defect: thrombus masquerading as a myxoma. *Ann Thorac Surg* 2007; 84:1742-1744.
2. Oginosawa Y, Abe H, Nakashima Y. The incidence and risk factors for venous obstruction after implantation of transvenous pacing leads. *Pacing Clin Electrophysiol* 2002;25:1605-1616.
3. Hartier L, Bera J, Delomez M, et al. Free-floating thrombi in right heart: diagnosis, management, and prognostic indexes in 38 consecutive patients. *Circulation* 1999;99:2779-2783
4. Barakat K, Robinson MN, Spurrell RA. Transvenous pacing lead-induced thrombosis: a series of cases with review of the literature. *Cardiology* 2000; 93:142-148.
5. Rose PS, Punjabi NM, Pearse DB. Treatment of right heart thromboemboli. *Chest* 2002; 121:806-814.
6. Blann AD, Lip GY. Lip. Atrial Fibrillation and Thrombosis: The Missing Molecular Links. *JACC* 2013; 61:861-862.
7. Kaskia JC, Arrebola AL. Inflammation and Thrombosis in Atrial Fibrillation. *Rev Esp Cardiol* 2011; 64 :551-553.
8. Nicolaou N, Becker A, Mc Michael G, Nicolaou V. Giant atrial thrombus presenting as a tumor. *Int J Surg Case Reports* 2013; 4:62-64.
9. Natarajan A, Tan S, Patel HN, Chukwu C, Harkness A, Harris S. Mass in the Left Atrial Appendage: A Therapeutic Dilemma. *Can J Cardiol* 2013; 29(10):1329.e13-1329.e15.
10. Yang EH, Moriarty JM, Lluri G, Aboulhosn JA. Giant left atrial appendage mimicking a mediastinal mass in a new diagnosis of atrial septal defect and pulmonic stenosis. *Int J Cardiol*. 2014; 175 (2):e27–e29.