

Duodenal Perforation by an Ingested Nail

Cihan Bedel¹, Önder Tomruk¹, Sadiye Yolcu², Levent Albayrak²

¹Suleyman Demirel University
Department of Emergency Medicine
Isparta/Turkey
²Bozok University Department of
Emergency Medicine Yozgat/Turkey

ABSTRACT

Foreign body ingestion is a rare gastrointestinal entity in adults. Foreign bodies generally do not cause any complications and pass through the gastrointestinal tract spontaneously within a week. 10%-20% of them need endoscopic management, and about 1% of them require surgery. In adults, foreign body ingestion can also occur, especially in people with intellectual disabilities, alcoholics, and in those without teeth, but it also can result from accidental swallowing. We present a case of foreign bodies ingestion by a mentally retarded patient with perforation of duodenum.

Keywords: Duodenum perforation, ingested nail, mentally retarded patient, acute abdomen

INTRODUCTION

Foreign body ingestion is a rare gastrointestinal entity in adults. Foreign bodies generally do not cause any complications and pass through the gastrointestinal tract spontaneously within a week [1]. 10%-20% of them need endoscopic management, and about 1% of them require surgery [2]. In adults, foreign body ingestion can also occur, especially in people with intellectual disabilities, alcoholics, and in those without teeth, but it also can result from accidental swallowing [3]. We present a case of foreign bodies ingestion by a mentally retarded patient with perforation of duodenum.

Case

In the case study presented, a 29-year-old female was presented with a complaint due to abdominal pain, nausea and vomiting and fever for nearly 3 days. She was diagnosed as mild level mentally retarded. She had a medical history of epilepsy requiring medication, there was no other chronic diseases. Her first vital signs were as follows: temperature, 38.4 °C; blood pressure, 100/70 mm Hg; respiratory rate, 24 /min; pulse rate, 105 beats/min; and oxygen saturation was 96% as measured using the pulse oximeter. In electrocardiogram; there

was a sinus tachycardia. Her physical examination was remarkable, rigid, distended abdomen with tenderness, guarding and rebound to palpation in the right lower abdominal and periumbilical region with a sign of peritonitis. The laboratory blood results showed. White blood cells were $15.80010^3/\mu\text{L}$ with an absolute neutrophil count of 75.4%, biochemistry and urine tests were normal limits. Chest x-ray was normal, while there were intensive radiopaque images in the abdominal X-ray. Abdominal computed tomography performed for an initial diagnosis of perforation (Figure 1). In abdominal computed tomography; there was a 11 cm hyperdense lesion extending to right psoas muscle which was penetrating the second part of the duodenum posterior wall (Figure 2). Around the view 14 x 5.5 cm size of the abscess in the psoas muscle was observed, abscess throughout the along the inferior iliac muscle. Contamination was observed in the right retroperitoneal adipose tissue. The patient was taken to the operating room for exploratory laparotomy and removal of foreign body. Nail pulled into the duodenum, transferred into the stomach. Nail was removed by gastrostomy in proximal gastric corpus. Primary repair was performed to stomach. The patient had an uneventful postoperative course and was discharged on postoperative 10th day.

Corresponding Author:

Levent Albayrak
Bozok University Department of
Emergency Medicine, Yozgat, Turkey
Email: drleventalbayrak@yahoo.com

Received: 10.02.2018,
Accepted: 04.08.2018
DOI: 10.5799/jcei.458763

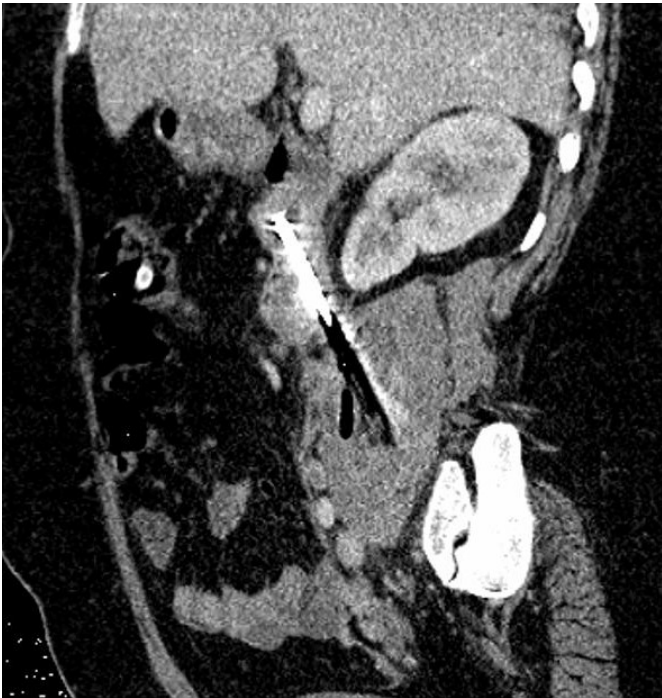


Figure 1. Abdominal computed tomography image of the patient

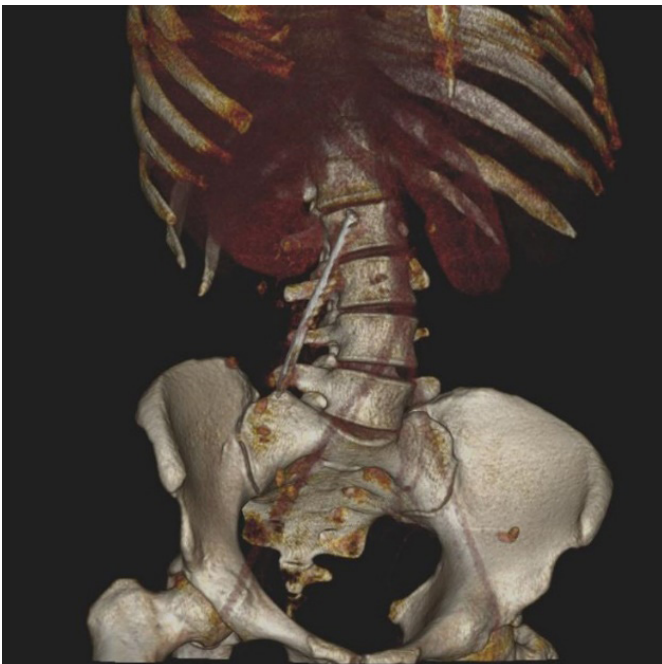

Figure 2. Abdominal three dimensional computed tomography of patient

DISCUSSION

All the ingested foreign bodies, less than 1% causes perforation of the gastrointestinal tract [4]. Sharp and elongated objects most likely penetrate bowel or oesophageal mucosal lining and may cause bowel perforation [5]. Perforations are more common

in ileocecal region. metallic objects, like needles or elongated objects such as fish bones, chicken bones, and tooth picks are the foreign bodies most frequently reported, causing a perforation. In many cases, these types of perforations do not occur acutely or cause acute symptoms. The object may only partially perforate the bowel wall and produce a chronic inflammatory process that has few symptoms, being discovered months or years later. Surgeons advocate conservative treatment for asymptomatic patients with foreign body ingestion. Endoscopic removal is proposed for pointed objects or objects bigger than 2.5 cm located in the stomach. Objects longer than 6 to 8 cm located in the stomach should be removed by endoscopy or laparoscopy. Neither the current series nor the literature can provide a firm answer to the advisability of early operation for FBs of a specific type that have passed beyond the reach of available endoscopes [4]. Patients with objects in the small bowel or colon should be treated conservatively unless there are complications, or they fail to progress [2]. Our case is important and original because of few reports on mentally retarded patient with due duodenal perforation and abscess formation by ingested nail [6].

Radiologic imaging takes an important role in determining the location. Plain x-ray graphs are the first preferred imaging modality. If the ingested object is radio-opaque, plain graphics could give information about the presence and localization.

Foreign body ingestion can be seen in adults, especially in those with intellectual disabilities. Mentally retarded patient who admitted to emergency department recurrent physical examinations should be performed, emergent computed tomography is required if peritonitis symptoms presence. In mental retardation patients who admits emergency department with abdominal pain, more detailed physical examinations should be performed fast imaging may play a role in saving their lives.

Declaration of interest: The authors report no conflicts of interest.

Financial Disclosure: No financial support was received.

REFERENCES

1. Ozkan Z, Kement M, Kargi AB, Censur Z, Gezen FC, Vural S, et al. An interesting journey of an ingested needle: a case report and review of the literature on extra-abdominal migration of ingested foreign bodies. *J Cardiothorac Surg.* 2011;6:77.
2. Ribas Y, Ruiz-Luna D, Garrido M, Bargalló J, Campillo F. Ingested foreign bodies: do we need a specific approach .when treating inmates? *Am Surg.* 2014;80:131-7.
3. Telford JJ. Management of ingested foreign bodies. *Can J Gastroenterol.* 2005;19:599-601.
4. Velitchkov NG, Grigorov GI, Losanoff JE, et al. Ingested foreign bodies of the gastrointestinal tract: retrospective analysis of 542 cases. *World J Surg.* 1996;20:1001-5.
5. Litovitz T, Schmitz BF. Ingestion of cylindrical and button batteries: an analysis of 2382 cases. *Pediatrics.* 1992;89:747-57.
6. Cebicci H, Alpaslan M. Foreign Bodies Ingested by a Mentally Retarded Turk *J Emerg Med.* 2015;15:57.